



European Vitreoretinal Society Macular Hole Study, Prognostic Factors for Anatomical and Functional Success

Barbara Parolini ¹, Zofia Michalewska ², Joshua S Hardin ³, Didier Ducournau ⁴, Ihab Saad Othman ⁵, Mohammed F. Faramawi ⁶, Ron A. Adelman ⁷, Ahmed B. Sallam ³

¹ Istituto Clinico S. Anna di Brescia, Italy

² Ophthalmic Clinic "Jasne Blonia", Rojna, Poland

³ Jones Eye Institute, University of Arkansas for Medical Sciences, Little Rock, Arkansas, USA

⁴ Clinique Sourdille, Nantes, France.

⁵ Ophthalmology Department, Cairo University, Egypt

⁶ Epidemiology Department, College of Public Health and Biomedical informatics, College of Medicine, University of Arkansas for Medical Sciences, Little Rock, Arkansas, USA

⁷ Ophthalmology Department, Yale University School of Medicine, New Haven, CT, USA

Epub: June 20, 2020

ABSTRACT

Background: To identify prognostic preoperative and intraoperative factors for anatomical and visual success of idiopathic macular hole (MH) surgery.

Methods: We conducted a non-randomized, collaborative multicenter study using data of 4207 MH surgery from 140 surgeons. Main study outcomes were anatomical closure and best corrected visual acuity (BCVA) improvement postoperative at 6-12 months.

Results: Information on anatomical success was available for 4138 eyes of 4207 operations. Anatomical closure of MH was achieved in 85.7% (3546 eyes). Closure was higher in smaller MH (stages 1-2 versus stage 3: OR=0.35; stage 2 versus stage 4: OR=0.16, and in MH with shorter duration before the operation (OR=0.94). Macular Holes were more likely to close when dyes were used to facilitate internal limiting membrane (ILM) peeling (odds ratio=1.73 to 3.58). The most important predictors of postoperative BCVA were the preoperative BCVA (estimate=0.39, p<0.001) and closure of the macular hole (estimate=0.34, p<0.001). We observed Larger improvement in BCVA in combined vitrectomy and phacoemulsification (estimate = 0.10) and post cataract surgery in phakic eyes (estimate=0.05). Retinal tears occurred in 5.1% of eyes, and were less with use of trocars (OR= -1.246) and in combined vitrectomy/ phacoemulsification surgery (OR= -0.688).

Conclusion: This international survey confirmed that staining with dyes improves anatomical results but not visual outcomes. After surgery, visual acuity improved during the first year, and final visual acuity was better in both pseudophakic eyes and eyes that underwent cataract surgery during the first year following MH repair.

KEY WORDS

Macular Hole; Vitrectomy; Inverted ILM Flap; Full-Thickness Macular Hole; ILM Peeling; Complete Vitrectomy; Combined Surgery; Positioning; Internal Limiting Membrane.

Copyright © 2020, Med Hypothesis Discov Innov Ophthalmol. This is an open-access article distributed under the terms of the Creative Commons Attribution-NonCommercial 4.0 International License (<http://creativecommons.org/licenses/by-nc/4.0/>) which permits copy and redistribute the material just in noncommercial usages, provided the original work is properly cited.

Correspondence to: Ahmed B. Sallam, MD, PhD; FRCOphth, Jones Eye Institute, University of Arkansas for Medical Sciences, Little Rock, AR 72211. Phone: 501-526-6000 x 1225; fax: 501-603-1289. E-mail: ahmedsallam11@yahoo.com

How to cite this article: Parolini B, Michalewska Z, Hardin JS, Ducournau D, Othman IS, Faramawi MF, Adelman RA, Sallam AB, European Vitreoretinal Society Macular Hole Study, Prognostic Factors for Anatomical and Functional Success. Med Hypothesis Discov Innov Ophthalmol. 2020; 9(3): 198-207.



INTRODUCTION

Idiopathic macular hole represents a common vitreoretinal pathology with an estimated population-incidence of approximately 9 cases annually [1]. While non-surgical modalities including intravitreal injection of ocriplasmin or gas are available for the treatment of macular hole (MH) [2, 3], surgical treatment with pars plana vitrectomy (PPV) has remained the main standard approach. Pars plana vitrectomy in MH surgery was first reported by Kelly and Wendel in 1991 [4]. Their initial success rate was 58%. Since then, surgical techniques have been refined and results from randomized controlled trials [5, 6] and contemporary real world studies reported an anatomical closure rate of 85% or more, and visual improvement of approximately 2-3 Snellen line [7-10].

Large macular holes are associated with worse visual prognosis and postoperative photoreceptor status has a confirmed correlation with visual acuity [11, 12]. However, there is paucity of evidence regarding the influence of intraoperative details on the results of MH surgery. Specifically, the role of intraocular tamponades [10, 13, 14], internal limiting membrane (ILM) peeling [15-20], ILM staining and the influence of the types of staining dye [21], and postoperative positioning [22-29] are still frequently debated. The main conclusion derived from a review of the literature is that meta-analyses and well-conducted, controlled trials are necessary to determine which surgical details are prognostic in MH surgery [30, 31]. Given the differences in the reporting outcomes in each study, and the varying surgical details, a meta-analysis would hardly be possible. A randomized clinical trial on a sufficiently large group of patients would also be costly, time consuming and may not reflect routine clinical care.

The European Vitreoretinal Society (EVRS) has previously conducted large studies examining the treatment of retinal detachment and macular edema in the real-world setting [32-37]. In the current investigation, a total of 4,207 operations for idiopathic MH performed by 140 surgeons from 28 countries were evaluated.

We aimed to report anatomical and functional outcomes of surgery for MH and to analyze the influence of different pre-, intra-operative factors. While one larger study has reviewed reoperation and retinal detachment with MH surgery [20], to our knowledge this is the largest comprehensive report on the anatomical and visual outcomes of MH in the literature to date.

METHODS

The EVRS Macular Hole Study is a non-randomized, multi-center retrospective survey designed to identify pre-, intra-, and post-operative factors determining anatomical and functional success of MH repair. Macular hole operations

reported between June 2008 and June 2012 by the society members were included. In total, 4,207 macular holes were operated by 140 vitreoretinal specialists from 28 countries across 4 continents (Figure 1 and 2 represent surgeons and eyes break down by country). The data gathered included lens status, hole duration, gauge, the use of trocars, suturing of scleral wounds, combined procedures, posterior hyaloid removal, internal limiting membrane (ILM) staining, ILM peeling, type of tamponade, completeness of tamponade, details of postoperative positioning, cataract formation, and complications including retinal tear and detachment (Table 1). The anatomical outcomes of repair were classified as follows; macular hole closed with edges not visible; hole open with edges visible and attached hole open with edges elevated; hole open with edges visible and attached. Only cases with macular hole closed and edges not visible were accounted as anatomical successes. Follow-up periods were 3-6 months, 6-12 months and 12+ (12-15) months after surgery.

To identify the most relevant predictors for best corrected visual acuity (BCVA) at three postoperative follow-up periods, a linear mixed effects model with two nested random effects was considered [38]. The model involved considering a surgeon's (or group of surgeons') random effect to account for surgeon heterogeneity and a patient's random effect nested within the surgeon's random effect to account for patient heterogeneity.

The considered potential predictors for BCVA were preoperative BCVA at different follow-up visits, stage, size (small, medium, large), hole duration, lens status, anatomical success, vitrectomy completeness (core, subtotal, complete), gauge, trocar, suturing of scleral wounds, combined phacoemulsification, type of dye, extent of posterior hyaloid removal (limited to the posterior pole or large), quality of tamponade, type of tamponade (complete versus incomplete), concentration of gas, quality of postoperative positioning (either strict prone positioning or patients advised not to look up, or no positioning at all), and duration of postoperative positioning. The model was estimated by the maximum likelihood method through the *lme* function in R package [39] *nlme* [40]. Please define yellow colors

The predictors of the probability of anatomical success were evaluated through a multivariate logistic model with a random intercept to account for surgeon heterogeneity. The considered potential predictors for anatomical success were MH stage, hole duration, crystalline lens status, vitrectomy completeness, combined phacoemulsification, type of dye to stain ILM, posterior hyaloid removal, quality of tamponade, type of tamponade, concentration of gas, quality of postoperative positioning and duration of postoperative positioning. The



model was estimated by the maximum likelihood method through R package *glmmML* [41]. For all multivariate

regression analyses, model selection was based on the stepwise method with Akaike Information Criterion [42].

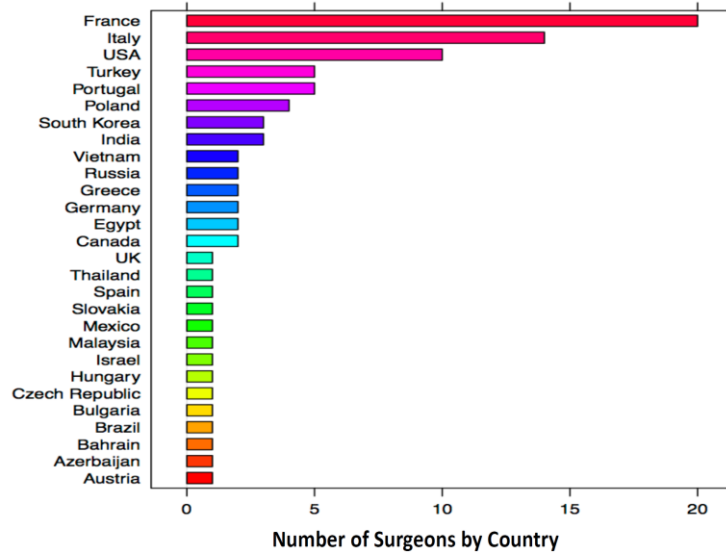


Figure 1. Number of Surgeons by Country.

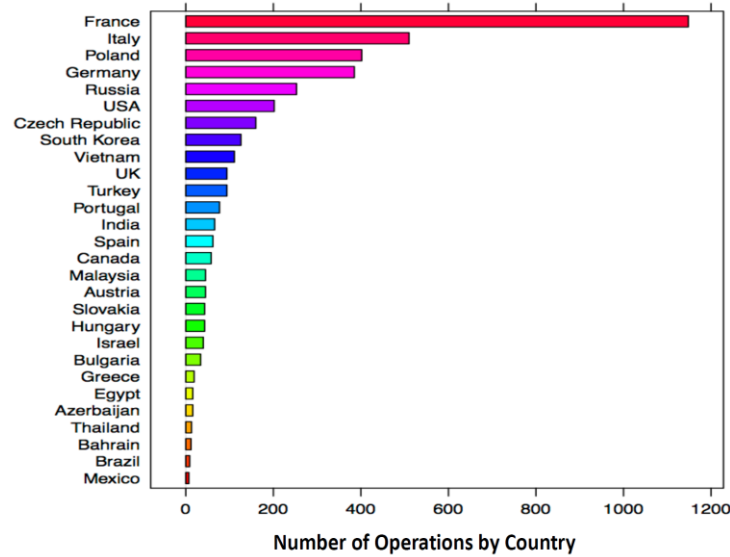


Figure 2. Number of Operations by Country.



Table 1. Variables That Surgeons Were Asked to Report to Assess Anatomical and Visual Outcome of MH Surgery

Clinical Findings	Pars Plana Vitrectomy	Additional Intraoperative details	Tamponade	Anatomical and Visual Outcomes	Postoperative Complications
<ul style="list-style-type: none"> • Stage of FTMH • FTMH duration • Pre-operative BCVA 	<ul style="list-style-type: none"> • Date of operation • Gauge • Trocar use • Suturing of scleral wounds • Combined phacoemulsification vitrectomy • Special techniques • Intraoperative complications 	<ul style="list-style-type: none"> • ILM peeling (yes/ no) • Dye used (none, trypan blue/ membrane blue, brilliant blue, Indocyanine green, other) • Peeling (100% sure/ not sure) • Technique of peeling • Complications of operation 	<ul style="list-style-type: none"> • Type of tamponade (air, SF6, C2F6, C3F8, silicone oil) • Complete (≥80%) fill/ Incomplete tamponade • Special techniques • Postoperative positioning (none, just look down, prone positioning) • Duration of postoperative positioning 	<ul style="list-style-type: none"> • FTMH closed (edges not visible) / flat edges/elevated edges • BCVA 3-6 months • BCVA 6-12 months • BCVA 12-15+ (12+) months 	<ul style="list-style-type: none"> • Cataract • Retinal tear • Retinal detachment • MH reoperation • Hypotony

FTMH: full thickness macular hole; BCVA: best corrected visual acuity; ILM: internal limiting membrane; MH: macular hole

Table 2. Odds Ratios With 95% Confidence Intervals (CI) in Parentheses and P-Values for the Regression Coefficients of the Selected Logistic Mixed Effects Model for the Probability of Anatomical Closure of Macular Hole.

Coefficients	Odds ratio (95% CI)	p-value
Stage		
Stage 3 FTMH	0.35 (0.20, 0.61)	<0.001
Stage 4 FTMH	0.16 (0.09, 0.28)	<0.001
FTMH duration	0.94 (0.91, 0.97) x 10 ⁻³	<0.001
Type of Dye		
Brilliant blue	1.73 (1.05, 2.86)	0.031
Indocyanine green	2.51 (1.34, 4.69)	0.004
Trypan/Membrane blue	2.27 (1.12, 4.60)	0.023
Other	3.58 (1.31, 9.75)	0.013

FTMH: full thickness macular hole; P<0.05 in bold.

Table 3. Estimates With 95% Confidence Intervals (CI) in Parentheses and P-Values for the Regression Coefficients of the Selected Linear Mixed Effects Model for BCVA Variation in Macular Hole

Coefficients	Estimate (95% CI)	p-value
Preoperative BCVA	0.39 (0.35, 0.43)	<0.001
6-12 months BCVA	0.09 (0.08, 0.10)	<0.001
12+ months BCVA	0.11 (0.10, 0.13)	<0.001
MH closed	0.34 (0.31, 0.38)	<0.001
Stage 3 MH	-0.06 (-0.09, -0.02)	0.002
Stage 4 MH	-0.11 (-0.15, -0.07)	<0.001
MH duration	-0.78 (-1.16, -0.41) x 10 ⁻³	<0.001
Incomplete intraocular tamponade	0.05 (0.00, 0.10)	0.075
Pseudophakia	0.05 (0.02, 0.09)	0.001
Combined phacoemulsification, lens implantation and vitrectomy	0.10 (0.06, 0.14)	<0.001
Duration of postoperative positioning	-0.11 (-0.18, -0.04) x 10 ⁻¹	0.002

BCVA: best corrected visual acuity; MH: macular hole; P<0.05 in bold.

Table 4. Odds Ratios With 95% Confidence Intervals (CI) in Parentheses and P-Values for the Regression Coefficients of The Selected Logistic Mixed Effects Model for the Probability of Successive Cataract Surgery following Macular Hole Surgery. P<0.05 in bold.

Coefficients	Odds ratio (95% CI)	p-value
Transconjunctival vitrectomy	0.43 (0.26, 0.72)	0.001
Gas dilution	1.18 (1.02, 1.36) x 10 ⁻¹	0.023
C3F8 gas versus C2F6 gas	2.02 (1.04, 3.92)	0.038
SF6 gas versus C2F6 gas	1.42 (0.75, 2.68)	0.277

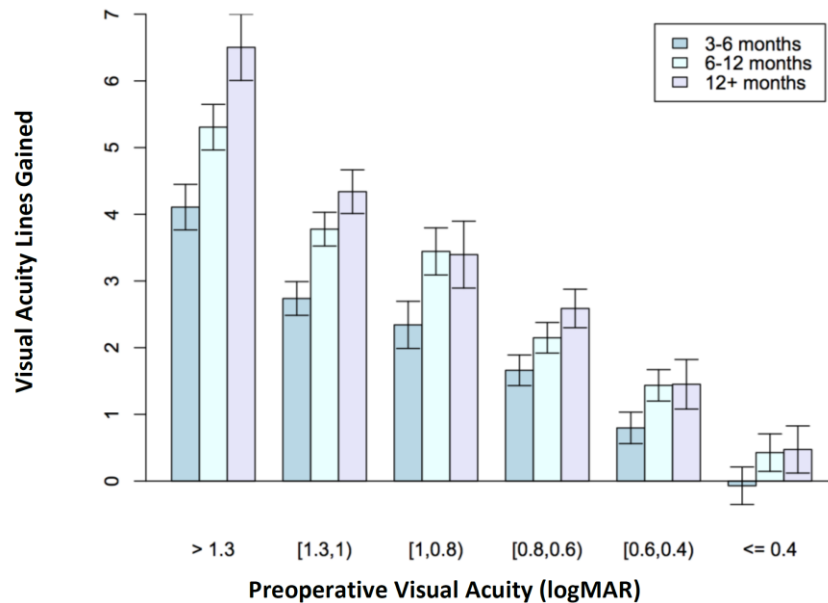


Figure 3. Postoperative Visual Acuity Lines Gained as a Function of Preoperative Vision in Logarithm of the Minimum Angle of Resolution (LogMAR) With 95% Confidence Intervals for Average Levels. 3-6 months: 3-6 months Postoperation; 6-12 months: 6-12 months Postoperation; 12+ months: 12-15 Months Postoperation.

RESULTS

Preoperative characteristics

Information on stage of MH was available for 3633 of 4207 (86.4%) eyes. Stage 1 MH was observed in 149 eyes (4.1% of cases with information about stage), stage 2 in 661 eyes (18.2%), stage 3 in 1294 eyes (35.6%) and stage 4 in 1529 eyes (42.1%). Stages 1 and 2 were merged since the frequency of stage 1 holes was considered low for reliable statistical analysis. Information about lens status was available for all but seven eyes. At the time of surgery, 0.4% (15 eyes) of patients were aphakic, 26.2% (1,100 eyes) were pseudophakic and 73.5% (3,085 eyes) phakic. Combined phacoemulsification, lens implantation and vitrectomy surgery were performed in 25% of initially phakic eyes.

Anatomical Results

Information on anatomical success was available for 4138 of 4207 eyes. Overall anatomical success rate, defined as complete closure with edges not visible, was 85.7% (3546 eyes). Anatomical failure, with flat open MH was observed in 7.7% (318 eyes) of cases, and with elevated edges in 6.6% (274 eyes). The selected logistic mixed model for anatomical success is summarized in Table 2. Anatomical success was higher in smaller macular holes (stages 1-2 versus stage 3: odds ratio=0.35, $p=0.001$; stage 2 versus

stage 4: odds ratio=0.16, $p<0.001$) and in macular holes with shorter durations before the operation (odds ratio=0.94, $p<0.001$). When eyes with stage 2 macular holes were analyzed separately, the results were similar to those of the group including stages 1 and 2. Macular Holes were more likely to close when dyes were used to facilitate ILM peeling (odds ratio=1.73 to 3.58), compared to without the use of dyes; however, there were no statistically significant differences between various types of dyes (Indocyanine Green, Trypan/Membrane blue and Brilliant blue).

Visual Acuity Results

Figure 3 displays the visual acuity lines gained as a function of preoperative Logarithm of the Minimum Angle of Resolution (LogMAR) VA. Improvement in postoperative BCVA was statistically significant at all successive follow-up intervals (3-6 months versus 6-12: estimate=0.09, $p<0.001$; 3-6 versus 12+: estimate=0.11, $p<0.001$). The selected linear mixed model for BCVA variation is summarized in Table 3. The most important predictors of postoperative BCVA were the preoperative BCVA (estimate=0.39, $p<0.001$) and postoperative closure of the macular hole (estimate=0.34, $p<0.001$).

Postoperative BCVA was inversely associated with the duration of symptoms (estimate = -0.78×10^{-3} , $p<0.001$) and the stage of hole at the time of operation (stage 2 versus



stage 3: estimate = -0.06, $p=0.002$, stage 2 versus stage 4: estimate = -0.11, $p<0.001$). The role of ILM peeling on functional and anatomical results could not be evaluated, as most (95.7%) surgeons peeled the ILM. The effect of incomplete versus complete tamponade on BCVA was not significant (estimate = 0.05, $p=0.075$) and the effect of postoperative positioning on BCVA was negatively related to its duration (estimate = -0.11×10^{-1} , $p=0.002$).

An improvement in BCVA was observed for combined vitrectomy and phacoemulsification (estimate = 0.10, $p<0.001$) as well as after cataract surgery regarding phakic eyes (estimate = 0.05, $p=0.001$). The average number of logMAR lines gained after 12 months was 4.1 ± 4.09 lines for eyes undergoing combined surgery and 4.41 ± 3.62 for those who subsequently underwent cataract surgery and was not different ($p=0.168$).

Special Techniques

The inverted ILM flap technique was used in a small sample of eyes: 238 eyes (5.6%), predominantly in stage 4 macular holes (13 % of stage 4 macular holes were operated using ILM flap). Better anatomical and visual outcomes were noted regarding macular hole closures (odds ratio = 14.45, $p<0.001$) and BCVA (estimate = 1.42×10^{-1} , $p=0.049$) when this technique was used compared to ILM peel in this subset of eyes.

Complications

Of 3085 initially phakic eyes, 1095 (35.5%) underwent subsequent cataract surgery. Survival time analysis showed that the median time for cataract surgery was 8 months and that only 26.4% were operated within the first month following vitrectomy. Risk factors analysis confirmed that both the use of transconjunctival vitrectomy with trocars (odds ratio = 0.43, $p=0.001$) and tamponades with lower gas concentrations (odds ratio = 1.18, $p=0.023$ for concentration of gas $\times 10^{-1}$) were negatively associated with cataract surgery (Table 4). However, the use of C3F8 was more highly associated with cataract surgery than C2F6 (odds ratio = 2.02, $p=0.038$), while there was no difference in the odds of cataract surgery comparing SF6 and C2F6 (odds ratio = 1.42, $p=0.277$).

Regarding other complications, repeated surgery was performed in 24.3% of eyes with postoperative elevated edges, the results of which were not recorded. Retinal tears occurred in 5.1% of cases. The logistic mixed effects model for the probability of retinal tears indicated that use of trocars (odds ratio = -1.246, $p\text{-value} < 0.001$) and combining surgery with cataract (odds ratio = -0.688, $p\text{-value} = 0.004$) were associated with a lower risk of retinal tears. Subsequent rhegmatogenous retinal detachment occurred in 3.6% of cases. Transient postoperative

hypotony was observed in ten eyes, which was too low for statistical analysis. In these cases, no scleral sutures were used.

DISCUSSION

Surgery for macular hole is a commonly performed vitreoretinal operation with usually favorable outcomes [43]. Accordingly, there is a considerable clinical interest in the outcome of surgery, and the success rate for macular hole repair is often used as an indicator for evaluating vitreoretinal surgeons' performance. It is therefore important to present large outcome data from different surgeons to benchmark against, and to analyze the factors influencing the functional and anatomical outcomes for MH surgery. Herein, we presented the results of 4207 eyes with MH surgery from 140 surgeons, the largest comprehensive report to date.

While one recent retrospective study reported no difference in outcomes based on the duration of symptoms [44], this study confirmed the findings of earlier studies indicating that anatomical and functional successes are more often achieved in smaller macular holes with shorter durations and those with better preoperative visual acuity [45-47]. The duration of symptoms is a subjective parameter and should be interpreted cautiously. We also found that visual acuity improves during the first 12 months of surgery. This is also true for stage IV, chronic macular holes, and may be explained by restoration of foveal contour and the ellipsoid zone continuity [48].

We found that almost a half of patients underwent phacoemulsification during the study period. Better final BCVA was achieved in pseudophakic eyes and in those who underwent subsequent cataract surgery. However, in our study, timing of cataract surgery (simultaneous versus delayed) had no influence on the final 12-months outcome, which was previously observed in a small retrospective analysis [10].

One recent study showed that improvement with phacoemulsification after MH surgery is associated with better vision-related quality of life and recommended combined surgery [49]. Thus, it may be reasonable to schedule patients for phacoemulsification soon after vitrectomy for MH to offer a prompt improvement in vision.

Regarding tamponades, the type and dilution of gas did not significantly impact the anatomical or functional results. This is in line with a recent meta-analysis that looked at the outcome of macular hole surgery operated with SF6 versus C3F8 gas [14], however, a large retrospective registry study indicated better vision in eyes operated



with short acting gas [10]. Recent studies have also continued to debate postoperative positioning [29, 50, 51], with one recent meta-analysis supported the use of face down positioning [28]. In this series, we observed worse functional results in patients who were advised longer periods of postoperative positioning. It might be because surgeons might have advised strict positioning in more complex cases. Thus, it may be reasonable to use shorter-acting gases such as SF₆ and shorter positioning to reduce patient discomfort, improve adherence, and enable earlier airplane travel. However, as this study was not randomized, the data on positioning should be interpreted with caution.

Peeling of the ILM has been shown to be associated with improved anatomical success, however, its influence on visual success remains unclear. Data from a recent registry-based study from the New Zealand and Australia demonstrated that while peeling of the ILM increased the anatomical closure rate [10] this did not lead to better visual acuity outcomes at 3 or 12 months. In contrast, a meta-analysis of 4 randomized controlled studies conducted in 2014 demonstrated that ILM peeling was associated with a significant albeit small (approximately 1 LogMAR) visual improvement over no ILM peeling at 3 months [52]. In the present study, 95.7% of surgeons chose to peel the ILM, thus preventing a comparison. The use of staining for the purpose of ILM peeling was an important predictive factor of anatomical, but not functional success. The difference between the types of dyes was not statistically significant.

The inverted ILM flap technique was previously reported to increase the success rate in the treatment of large, stage 4 macular holes and macular holes associated with high myopia [9, 53, 54]. One recent retrospective study compared 300 eyes with ILM peel and 320 eyes with the inverted ILM flap technique and indicated a difference in overall success rates of 78.6% and 95.6%, respectively in eyes with MH \geq 400 [55]. We confirm the results of these studies, showing that this technique improves anatomical and functional results in large macular holes.

We found a 5% intraoperative rate of iatrogenic retinal tears and risk was lower in transconjunctival vitrectomy with the use of trocars. The reported rates of retinal tears with MH surgery in the literature vary widely with some studies reporting figures as high as 16% [56]. Our results are comparable to those of a large national database study from the United Kingdom that reported retinal tears in 7% with PPV for MH.

The results of our study need to be interpreted with caution because of the risk of bias associated with nonrandomization and its retrospective design. Similar to

other database studies, there were missing data in our studies which may affect the study quality and there was a variation in techniques used based on surgeons' preference. Considering that a large number of physicians for more than 20 countries participated in this study, we expect the effect of these biases to be small. The large scale of data also makes it representative of retinal physicians' practice and suitable for surgeon benchmarking, as compared to studies originating from selected institutions.

CONCLUSION

This multicenter survey confirms earlier data from smaller studies which showed better results in low-stage, short-term macular holes with good initial visual acuity. Phacoemulsification, performed before, during or after vitrectomy was one of the most important factors influencing functional results. In stage IV macular holes, the inverted ILM flap technique was associated with greater anatomical and functional success. Internal limiting membrane staining improved anatomical results without a significant difference between dyes. Moreover, longer positioning and use of long-acting gases or silicone oil were not shown to improve outcomes. A prospective study might add more insight on the effect of tamponade type and postoperative positioning on macular hole closure.

ETHICAL DECLARATIONS

Ethical Approval: An informed consent was obtained from all individual participants included in the study. The study follows the Tenets of the Declaration of Helsinki. The EVRS Committees approved the study design and ethical aspects of the investigation.

Conflict of Interest: None.

FUNDING

Oertli Instrumente AG and Maclodio Lions Club of Brescia, Italy supported the study with a financial grant. The funders had no role in study design, data collection and analysis, decision to publish, or preparation of the manuscript.

ACKNOWLEDGMENTS

Anja Leppich, the EVRS administrative director who led the data collection. Cristiano Varin, PhD (Ca' Foscari University, Venice, Italy), and Annamaria Guolo, PhD (University of Padova, Italy) for their help with the statistics.



REFERENCES

1. McCannel CA, Ensminger JL, Diehl NN, Hodge DN. Population-based incidence of macular holes. *Ophthalmology*. 2009;116(7):1366-9. doi: [10.1016/j.ophtha.2009.01.052](https://doi.org/10.1016/j.ophtha.2009.01.052) pmid: [19576500](https://pubmed.ncbi.nlm.nih.gov/19576500/)
2. Stalmans P, Benz MS, Gandorfer A, Kampik A, Girach A, Pakola S, et al. Enzymatic vitreolysis with ocriplasmin for vitreomacular traction and macular holes. *N Engl J Med*. 2012;367(7):606-15. doi: [10.1056/NEJMoa1110823](https://doi.org/10.1056/NEJMoa1110823) pmid: [22894573](https://pubmed.ncbi.nlm.nih.gov/22894573/)
3. Neffendorf JE, Simpson ARH, Steel DHW, Desai R, McHugh DA, Pringle E, et al. Intravitreal gas for symptomatic vitreomacular adhesion: a synthesis of the literature. *Acta Ophthalmol*. 2018;96(7):685-91. doi: [10.1111/aos.13547](https://doi.org/10.1111/aos.13547) pmid: [28857483](https://pubmed.ncbi.nlm.nih.gov/28857483/)
4. Kelly NE, Wendel RT. Vitreous surgery for idiopathic macular holes. Results of a pilot study. *Arch Ophthalmol*. 1991;109(5):654-9. doi: [10.1001/archophth.1991.01080050068031](https://doi.org/10.1001/archophth.1991.01080050068031) pmid: [2025167](https://pubmed.ncbi.nlm.nih.gov/2025167/)
5. Kim JW, Freeman WR, Azen SP, El-Haig W, Klein DJ, Bailey IL. Prospective Randomized Trial of Vitrectomy or Observation for Stage 2 Macular Holes. *American J Ophthalmology*. 1996;121(6):605-14. doi: [10.1016/s0002-9394\(14\)70625-7](https://doi.org/10.1016/s0002-9394(14)70625-7)
6. Freeman WR, Azen SP, Kim JW, el-Haig W, Mishell DR, 3rd, Bailey I. Vitrectomy for the treatment of full-thickness stage 3 or 4 macular holes. Results of a multicentered randomized clinical trial. The Vitrectomy for Treatment of Macular Hole Study Group. *Arch Ophthalmol*. 1997;115(1):11-21. doi: [10.1001/archophth.1997.01100150013002](https://doi.org/10.1001/archophth.1997.01100150013002) pmid: [9006420](https://pubmed.ncbi.nlm.nih.gov/9006420/)
7. Ando F, Sasano K, Ohba N, Hirose H, Yasui O. Anatomic and visual outcomes after indocyanine green-assisted peeling of the retinal internal limiting membrane in idiopathic macular hole surgery. *Am J Ophthalmol*. 2004;137(4):609-14. doi: [10.1016/j.ajo.2003.08.038](https://doi.org/10.1016/j.ajo.2003.08.038) pmid: [15059697](https://pubmed.ncbi.nlm.nih.gov/15059697/)
8. Beutel J, Dahmen G, Ziegler A, Hoerauf H. Internal limiting membrane peeling with indocyanine green or trypan blue in macular hole surgery: a randomized trial. *Arch Ophthalmol*. 2007;125(3):326-32. doi: [10.1001/archophth.125.3.326](https://doi.org/10.1001/archophth.125.3.326) pmid: [17353402](https://pubmed.ncbi.nlm.nih.gov/17353402/)
9. Michalewska Z, Michalewski J, Adelman RA, Nawrocki J. Inverted internal limiting membrane flap technique for large macular holes. *Ophthalmology*. 2010;117(10):2018-25. doi: [10.1016/j.ophtha.2010.02.011](https://doi.org/10.1016/j.ophtha.2010.02.011) pmid: [20541263](https://pubmed.ncbi.nlm.nih.gov/20541263/)
10. Essex RW, Hunyor AP, Moreno-Betancur M, Yek JTO, Kingston ZS, Campbell WG, et al. The Visual Outcomes of Macular Hole Surgery: A Registry-Based Study by the Australian and New Zealand Society of Retinal Specialists. *Ophthalmol Retina*. 2018;2(11):1143-51. doi: [10.1016/j.oret.2018.04.022](https://doi.org/10.1016/j.oret.2018.04.022) pmid: [31047553](https://pubmed.ncbi.nlm.nih.gov/31047553/)
11. Michalewska Z, Michalewski J, Cisiecki S, Adelman R, Nawrocki J. Correlation between foveal structure and visual outcome following macular hole surgery: a spectral optical coherence tomography study. *Graefes Arch Clin Exp Ophthalmol*. 2008;246(6):823-30. doi: [10.1007/s00417-007-0764-5](https://doi.org/10.1007/s00417-007-0764-5) pmid: [18386040](https://pubmed.ncbi.nlm.nih.gov/18386040/)
12. Yamashita T, Sakamoto T, Terasaki H, Iwasaki M, Ogushi Y, Okamoto F, et al. Best surgical technique and outcomes for large macular holes: retrospective multicentre study in Japan. *Acta Ophthalmol*. 2018;96(8):e904-e10. doi: [10.1111/aos.13795](https://doi.org/10.1111/aos.13795) pmid: [29671948](https://pubmed.ncbi.nlm.nih.gov/29671948/)
13. Bainbridge J, Herbert E, Gregor Z. Macular holes: vitreoretinal relationships and surgical approaches. *Eye (Lond)*. 2008;22(10):1301-9. doi: [10.1038/eye.2008.23](https://doi.org/10.1038/eye.2008.23) pmid: [18327161](https://pubmed.ncbi.nlm.nih.gov/18327161/)
14. Hecht I, Mimouni M, Blumenthal EZ, Barak Y. Sulfur Hexafluoride (SF6) versus Perfluoropropane (C3F8) in the Intraoperative Management of Macular Holes: A Systematic Review and Meta-Analysis. *J Ophthalmol*. 2019;2019:1820850. doi: [10.1155/2019/1820850](https://doi.org/10.1155/2019/1820850) pmid: [30993017](https://pubmed.ncbi.nlm.nih.gov/30993017/)
15. Haritoglou C, Kampik A, Langhals H. II. Indocyanine Green Should Not Be Used to Facilitate Removal of the Internal Limiting Membrane in Macular Hole Surgery. *Survey of Ophthalmology*. 2009;54(1):138-41. doi: [10.1016/j.survophthal.2008.10.016](https://doi.org/10.1016/j.survophthal.2008.10.016)
16. Ishida M, Ichikawa Y, Higashida R, Tsutsumi Y, Ishikawa A, Imamura Y. Retinal displacement toward optic disc after internal limiting membrane peeling for idiopathic macular hole. *Am J Ophthalmol*. 2014;157(5):971-7. doi: [10.1016/j.ajo.2014.01.026](https://doi.org/10.1016/j.ajo.2014.01.026) pmid: [24503409](https://pubmed.ncbi.nlm.nih.gov/24503409/)
17. Mester V, Kuhn F. Internal limiting membrane removal in the management of full-thickness macular holes. *American J Ophthalmology*. 2000;129(6):769-77. doi: [10.1016/s0002-9394\(00\)00358-5](https://doi.org/10.1016/s0002-9394(00)00358-5)
18. Thompson JT, Haritoglu C, Kampik A, Langhals H. Should Indocyanine green should be used to facilitate removal of the internal limiting membrane in macular hole surgery. *Surv Ophthalmol*. 2009;54(1):135-8. doi: [10.1016/j.survophthal.2008.10.018](https://doi.org/10.1016/j.survophthal.2008.10.018) pmid: [19171215](https://pubmed.ncbi.nlm.nih.gov/19171215/)
19. Tognetto D, Grandin R, Sanguinetti G, Minutola D, Di Nicola M, Di Mascio R, et al. Internal limiting membrane removal during macular hole surgery: results of a multicenter retrospective study. *Ophthalmology*. 2006;113(8):1401-10. doi: [10.1016/j.ophtha.2006.02.061](https://doi.org/10.1016/j.ophtha.2006.02.061) pmid: [16877079](https://pubmed.ncbi.nlm.nih.gov/16877079/)
20. Vaziri K, Schwartz SG, Kishor KS, Fortun JA, Moshfeghi AA, Smiddy WE, et al. Rates of Reoperation and Retinal Detachment after Macular Hole Surgery. *Ophthalmology*. 2016;123(1):26-31. doi: [10.1016/j.ophtha.2015.09.015](https://doi.org/10.1016/j.ophtha.2015.09.015) pmid: [26505804](https://pubmed.ncbi.nlm.nih.gov/26505804/)
21. Kumagai K, Furukawa M, Ogino N, Uemura A, Larson E. Long-term outcomes of internal limiting membrane peeling with and without indocyanine green in macular hole surgery. *Retina*. 2006;26(6):613-7. doi: [10.1097/01.iae.0000236471.79066.fe](https://doi.org/10.1097/01.iae.0000236471.79066.fe) pmid: [16829801](https://pubmed.ncbi.nlm.nih.gov/16829801/)
22. Conart JB, Selton J, Hubert I, Trechot F, El Adssi H, Creuzot-Garcher C, et al. Outcomes of macular hole surgery with short-duration positioning in highly myopic eyes: a case-control study. *Ophthalmology*. 2014;121(6):1263-8. doi: [10.1016/j.ophtha.2013.12.005](https://doi.org/10.1016/j.ophtha.2013.12.005) pmid: [24480709](https://pubmed.ncbi.nlm.nih.gov/24480709/)
23. Guillaubey A, Malvitte L, Lafontaine PO, Jay N, Hubert I, Bron A, et al. Comparison of face-down and seated position after idiopathic macular hole surgery: a randomized clinical trial. *Am J Ophthalmol*. 2008;146(1):128-34. doi: [10.1016/j.ajo.2008.02.029](https://doi.org/10.1016/j.ajo.2008.02.029) pmid: [18440484](https://pubmed.ncbi.nlm.nih.gov/18440484/)



24. Lange CA, Membrey L, Ahmad N, Wickham L, Maclaren RE, Solebo L, et al. Pilot randomised controlled trial of face-down positioning following macular hole surgery. *Eye (Lond)*. 2012;26(2):272-7. doi: [10.1038/eye.2011.221](https://doi.org/10.1038/eye.2011.221) pmid: [21941361](https://pubmed.ncbi.nlm.nih.gov/21941361/)
25. Mulhern MG, Cullinane A, Cleary PE. Visual and anatomical success with short-term macular tamponade and autologous platelet concentrate. *Graefes Arch Clin Exp Ophthalmol*. 2000;238(7):577-83. doi: [10.1007/s004170000154](https://doi.org/10.1007/s004170000154) pmid: [10955659](https://pubmed.ncbi.nlm.nih.gov/10955659/)
26. Tornambe PE, Poliner LS, Grote K. Macular hole surgery without face-down positioning. A pilot study. *Retina*. 1997;17(3):179-85. doi: [10.1097/00006982-199705000-00001](https://doi.org/10.1097/00006982-199705000-00001) pmid: [9196926](https://pubmed.ncbi.nlm.nih.gov/9196926/)
27. Tranos PG, Peter NM, Nath R, Singh M, Dimitrakos S, Charteris D, et al. Macular hole surgery without prone positioning. *Eye (Lond)*. 2007;21(6):802-6. doi: [10.1038/sj.eye.6702339](https://doi.org/10.1038/sj.eye.6702339) pmid: [16575410](https://pubmed.ncbi.nlm.nih.gov/16575410/)
28. Xia S, Zhao XY, Wang EQ, Chen YX. Comparison of face-down posturing with nonsupine posturing after macular hole surgery: a meta-analysis. *BMC Ophthalmol*. 2019;19(1):34. doi: [10.1186/s12886-019-1047-8](https://doi.org/10.1186/s12886-019-1047-8) pmid: [30691441](https://pubmed.ncbi.nlm.nih.gov/30691441/)
29. Lindtjorn B, Krohn J, Austeng D, Fossen K, Varhaug P, Basit S, et al. Nonsupine Positioning after Macular Hole Surgery: A Prospective Multicenter Study. *Ophthalmol Retina*. 2019;3(5):388-92. doi: [10.1016/j.oret.2018.12.006](https://doi.org/10.1016/j.oret.2018.12.006) pmid: [31044728](https://pubmed.ncbi.nlm.nih.gov/31044728/)
30. Gupta D. Face-down posturing after macular hole surgery: a review. *Retina*. 2009;29(4):430-43. doi: [10.1097/IAE.0b013e3181a0bd01](https://doi.org/10.1097/IAE.0b013e3181a0bd01) pmid: [19359978](https://pubmed.ncbi.nlm.nih.gov/19359978/)
31. Tatham A, Banerjee S. Face-down posturing after macular hole surgery: a meta-analysis. *Br J Ophthalmol*. 2010;94(5):626-31. doi: [10.1136/bjo.2009.163741](https://doi.org/10.1136/bjo.2009.163741) pmid: [19767335](https://pubmed.ncbi.nlm.nih.gov/19767335/)
32. Adelman RA, Parnes AJ, Michalewska Z, Parolini B, Boscher C, Ducournau D, et al. Corrigendum to "Strategy for the Management of Diabetic Macular Edema: The European Vitreo-Retinal Society Macular Edema Study". *Biomed Res Int*. 2015;2015:694902. doi: [10.1155/2015/694902](https://doi.org/10.1155/2015/694902) pmid: [26798639](https://pubmed.ncbi.nlm.nih.gov/26798639/)
33. Adelman RA, Parnes AJ, Bopp S, Saad Othman I, Ducournau D, Evrs Macular Edema Study G. Corrigendum to "Strategy for the Management of Macular Edema in Retinal Vein Occlusion: The European VitreoRetinal Society Macular Edema Study". *Biomed Res Int*. 2015;2015:694690. doi: [10.1155/2015/694690](https://doi.org/10.1155/2015/694690) pmid: [26697492](https://pubmed.ncbi.nlm.nih.gov/26697492/)
34. Adelman RA, Parnes AJ, Ducournau D, European Vitreo-Retinal Society Retinal Detachment Study G. Strategy for the management of uncomplicated retinal detachments: the European vitreo-retinal society retinal detachment study report 1. *Ophthalmology*. 2013;120(9):1804-8. doi: [10.1016/j.ophtha.2013.01.070](https://doi.org/10.1016/j.ophtha.2013.01.070) pmid: [23601799](https://pubmed.ncbi.nlm.nih.gov/23601799/)
35. Adelman RA, Parnes AJ, Michalewska Z, Ducournau D, European Vitreo-Retinal Society Retinal Detachment Study G. Clinical variables associated with failure of retinal detachment repair: the European vitreo-retinal society retinal detachment study report number 4. *Ophthalmology*. 2014;121(9):1715-9. doi: [10.1016/j.ophtha.2014.03.012](https://doi.org/10.1016/j.ophtha.2014.03.012) pmid: [24766870](https://pubmed.ncbi.nlm.nih.gov/24766870/)
36. Adelman RA, Parnes AJ, Sipperley JO, Ducournau D, European Vitreo-Retinal Society Retinal Detachment Study G. Strategy for the management of complex retinal detachments: the European vitreo-retinal society retinal detachment study report 2. *Ophthalmology*. 2013;120(9):1809-13. doi: [10.1016/j.ophtha.2013.01.056](https://doi.org/10.1016/j.ophtha.2013.01.056) pmid: [23601805](https://pubmed.ncbi.nlm.nih.gov/23601805/)
37. Michalewska Z, Ducournau D, Adelman RA, Group ERS. How do vitrectomy parameters influence the results of rhegmatogenous retinal detachments repair? EVRS RD Study No. 3. *Acta Ophthalmol*. 2014;92(5):e416-7. doi: [10.1111/aos.12318](https://doi.org/10.1111/aos.12318) pmid: [24314312](https://pubmed.ncbi.nlm.nih.gov/24314312/)
38. Diggle P, Diggle PJ, Heagerty P, Liang K-Y, Heagerty PJ, Zeger S. *Analysis of longitudinal data*: Oxford University Press; 2002.
39. R Development Core Team R. R: A language and environment for statistical computing. R foundation for statistical computing Vienna, Austria; 2015.
40. Pinheiro J, Bates D, DebRoy S, Sarkar D, Team RC. *Linear and nonlinear mixed effects models*. R package version. 2015;3(57):1-122.
41. Brostrom G. *glmmML: Generalized linear models with clustering*. R package version 10. 2013.
42. Akaike H. A new look at the statistical model identification. *IEEE Transactions on Automatic Control*. 1974;19(6):716-23. doi: [10.1109/tac.1974.1100705](https://doi.org/10.1109/tac.1974.1100705)
43. Jackson TL, Donachie PH, Sparrow JM, Johnston RL. United Kingdom National Ophthalmology Database Study of Vitreoretinal Surgery: report 1; case mix, complications, and cataract. *Eye (Lond)*. 2013;27(5):644-51. doi: [10.1038/eye.2013.12](https://doi.org/10.1038/eye.2013.12) pmid: [23449509](https://pubmed.ncbi.nlm.nih.gov/23449509/)
44. Stene-Johansen I, Bragadottir R, Petrovski BE, Petrovski G. Macular Hole Surgery Using Gas Tamponade-An Outcome from the Oslo Retrospective Cross-Sectional Study. *J Clin Med*. 2019;8(5). doi: [10.3390/jcm8050704](https://doi.org/10.3390/jcm8050704) pmid: [31108955](https://pubmed.ncbi.nlm.nih.gov/31108955/)
45. Mester U, Becker M. [Prognostic factors in surgery of macular holes]. *Ophthalmologie*. 1998;95(3):158-62. doi: [10.1007/s003470050255](https://doi.org/10.1007/s003470050255) pmid: [9578693](https://pubmed.ncbi.nlm.nih.gov/9578693/)
46. Ullrich S, Haritoglou C, Gass C, Schaumberger M, Ulbig MW, Kampik A. Macular hole size as a prognostic factor in macular hole surgery. *Br J Ophthalmol*. 2002;86(4):390-3. doi: [10.1136/bjo.86.4.390](https://doi.org/10.1136/bjo.86.4.390) pmid: [11914205](https://pubmed.ncbi.nlm.nih.gov/11914205/)
47. Zou J, Zeng J. The macular microstructure repair and predictive factors of surgical outcomes after vitrectomy for idiopathic macular hole. *Inter J Ophthalmology*. 2019;12(5). doi: [10.18240/ijo.2019.05.25](https://doi.org/10.18240/ijo.2019.05.25)
48. Michalewska Z, Michalewski J, Nawrocki J. Continuous changes in macular morphology after macular hole closure visualized with spectral optical coherence tomography. *Graefes Arch Clin Exp Ophthalmol*. 2010;248(9):1249-55. doi: [10.1007/s00417-010-1370-5](https://doi.org/10.1007/s00417-010-1370-5) pmid: [20379735](https://pubmed.ncbi.nlm.nih.gov/20379735/)
49. Wang Y, Liang X, Gao M, Liu J, Liu L, Liu W. Vision-related quality of life after pars plana vitrectomy with or without combined cataract surgery for idiopathic macular hole



- patients. *Int Ophthalmol.* 2019;39(12):2775-83. doi: [10.1007/s10792-019-01124-6](https://doi.org/10.1007/s10792-019-01124-6) pmid: 31144239
50. Elborgy E, Starr M, Kotowski J, Chehade J, Iezzi R. No Face-down Positioning Surgery for the Repair of Chronic Idiopathic Macular Holes. *Retina.* 2018. doi: [10.1097/iae.0000000000002396](https://doi.org/10.1097/iae.0000000000002396)
51. Feist RM, Jr., Pomerleau DL, Feist R, Albert MA, Emond TL, Mason JO, 3rd, et al. Nonsupine positioning is preferred by patients over face-down positioning and provides an equivalent closure rate in 25- and 23-gauge macular hole surgery. *Retin Cases Brief Rep.* 2014;8(3):205-8. doi: [10.1097/ICB.0000000000000043](https://doi.org/10.1097/ICB.0000000000000043) pmid: 25372439
52. Spiteri Cornish K, Lois N, Scott NW, Burr J, Cook J, Boachie C, et al. Vitrectomy with internal limiting membrane peeling versus no peeling for idiopathic full-thickness macular hole. *Ophthalmology.* 2014;121(3):649-55. doi: [10.1016/j.ophtha.2013.10.020](https://doi.org/10.1016/j.ophtha.2013.10.020) pmid: 24314837
53. Kuriyama S, Hayashi H, Jingami Y, Kuramoto N, Akita J, Matsumoto M. Efficacy of inverted internal limiting membrane flap technique for the treatment of macular hole in high myopia. *Am J Ophthalmol.* 2013;156(1):125-31 e1. doi: [10.1016/j.ajo.2013.02.014](https://doi.org/10.1016/j.ajo.2013.02.014) pmid: 23622567
54. Michalewska Z, Michalewski J, Dulczewska-Cichecka K, Nawrocki J. Inverted internal limiting membrane flap technique for surgical repair of myopic macular holes. *Retina.* 2014;34(4):664-9. doi: [10.1097/IAE.0000000000000042](https://doi.org/10.1097/IAE.0000000000000042) pmid: 24263468
55. Rizzo S, Tartaro R, Barca F, Caporossi T, Bacherini D, Giansanti F. Internal Limiting Membrane Peeling Versus Inverted Flap Technique for Treatment of Full-Thickness Macular Holes: A Comparative Study in a Large Series of Patients. *Retina.* 2018;38 Suppl 1:S73-S8. doi: [10.1097/IAE.0000000000001985](https://doi.org/10.1097/IAE.0000000000001985) pmid: 29232338
56. Dogramaci M, Lee EJ, Williamson TH. The incidence and the risk factors for iatrogenic retinal breaks during pars plana vitrectomy. *Eye (Lond).* 2012;26(5):718-22. doi: [10.1038/eye.2012.18](https://doi.org/10.1038/eye.2012.18) pmid: 22344186